

# Clinical Pearl: Topical Timolol for Refractory Hypergranulation

Reid A. Waldman, MD; Gloria Lin, MD, MS; Brett Sloan, MD

Hypergranulation is a frequent complication of dermatologic surgery. Management of postoperative hypergranulation with routine wound care and/or topical silver nitrate often is effective, but refractory cases can be challenging given the paucity of treatment options. We present an alternative treatment of refractory hypergranulation using timolol ophthalmic gel forming solution.

*Cutis.* 2019;104:118-119.

After 2 weeks of treatment with topical timolol, resolution of the hypergranulation and re-epithelialization of the surgical sites was observed (Figure 2). Another patient presented with hypergranulation that developed following a traumatic injury on the left upper arm and had been treated unsuccessfully for several months at a wound care clinic with daily nonadherent sterile gauze dressings and both topical and oral antibiotics (Figure 3A).

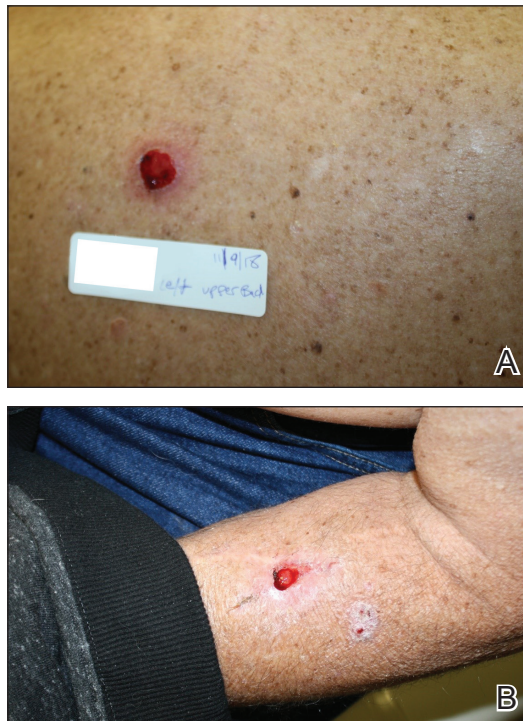## Practice Gap

Hypergranulation is a frequent complication of dermatologic surgery, especially when surgical defects are left to heal by secondary intention (eg, after electrodesiccation and curettage). Although management of postoperative hypergranulation with routine wound care, superpotent topical corticosteroids, and/or topical silver nitrate often is effective, refractory cases pose a difficult challenge given the paucity of treatment options. Effective management of these cases is important because hypergranulation can delay wound healing, cause patient discomfort, and lead to poor wound cosmesis.

## The Technique

If refractory hypergranulation fails to respond to treatment with routine wound care and topical silver nitrate, we prescribe twice-daily application of timolol maleate ophthalmic gel forming solution 0.5% for up to 14 days or until complete resolution of the hypergranulation is achieved. We counsel patients to continue routine wound care with daily dressing changes in conjunction with topical timolol application.

We initiated treatment with topical timolol in a patient who developed hypergranulation at 2 separate electrodesiccation and curettage sites that was refractory to 6 weeks of routine wound care with white petrolatum under nonadherent sterile gauze dressings and 2 subsequent topical silver nitrate applications (Figure 1).

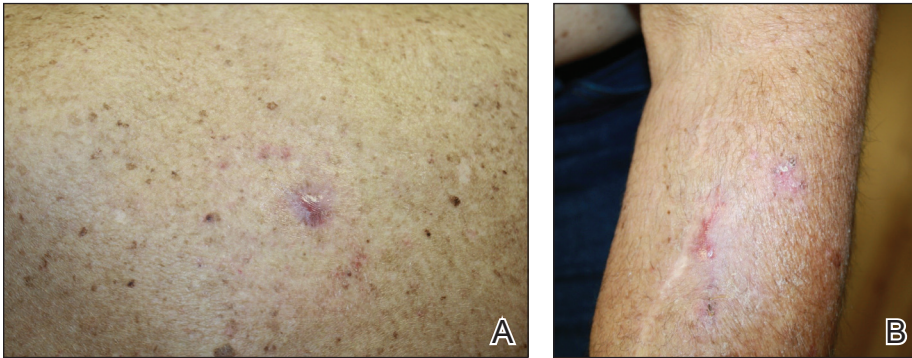


**FIGURE 1.** A and B, Electrodesiccation and curettage sites on the left side of the upper back and left forearm with hypergranulation that was refractory to routine wound care and topical silver nitrate application.

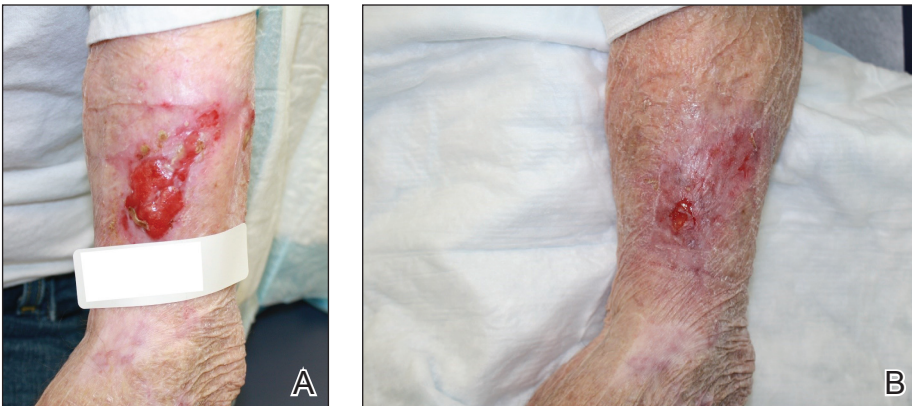
From the Dermatology Department, University of Connecticut Health Center, Farmington.

The authors report no conflict of interest.

Correspondence: Brett Sloan, MD, UConn Health Dermatology Department, 21 South Rd, Farmington, CT 06032 (steven.sloan@va.gov).



**FIGURE 2.** A and B, Re-epithelialized electrodesiccation and curettage sites on the left side of the upper back and left forearm following twice-daily treatment with timolol ophthalmic gel forming solution for 2 weeks.



**FIGURE 3.** A, Traumatic injury of the left upper arm complicated by hypergranulation. B, Re-epithelialized wound on the left upper arm following twice-daily treatment with timolol ophthalmic gel forming solution for 9 days.

After treatment for 9 days with topical timolol, resolution of the hypergranulation and re-epithelialization of the surgical sites was observed (Figure 3B).

### Practice Implications

Beta-blockers are increasingly being used for management of chronic nonhealing wounds since the 1990s when oral administration of propranolol initially was reported to be an effective adjuvant therapy for managing severe burns.<sup>1</sup> Since then, topical beta-blockers have been reported to be effective for management of ulcerated hemangiomas, venous stasis ulcers, chronic diabetic ulcers, and chronic nonhealing surgical wounds; however, there are no known reports of using topical beta-blockers for management of hypergranulation.<sup>2-5</sup> We found timolol ophthalmic gel to be an excellent second-line therapy for management of postoperative hypergranulation if

prior treatment with routine wound care and superpotent topical corticosteroids has failed. To date, we have found no reported adverse effects from the use of topical timolol for this indication that have required discontinuation of the medication. Use of this simple and safe intervention can be effective as a solution to a common postoperative condition.

### REFERENCES

1. Herndon DN, Hart DW, Wolf SE, et al. Reversal of catabolism by beta-blockade after severe burns. *N Engl J Med.* 2001;345:1223-1229.
2. Pope E, Chakkittakandiyil A. Topical timolol gel for infantile hemangiomas: a pilot study. *Arch Dermatol.* 2010;146:564-565.
3. Braun L, Lamel S, Richmond N, et al. Topical timolol for recalcitrant wounds. *JAMA Dermatol.* 2013;149:1400-1402.
4. Thomas B, Kurien J, Jose T, et al. Topical timolol promotes healing of chronic leg ulcer. *J Vasc Surg.* 2017;5:844-850.
5. Tang J, Dosal J, Kirsner RS. Topical timolol for a refractory wound. *Dermatol Surg.* 2012;38:135-138.